



# Minimally invasive operative techniques using high tech dentistry

BY DR ANDREW M. BROSTEK  
DR ANDREW J. BOCHENEK  
PROF. LAURENCE J. WALSH

The advent of the acid-etch technique by Buonocore in the 1950's and 60's brought about an enormous change in clinical operative dentistry. No longer was it necessary to prepare a tooth to adapt to the limitations of the amalgam restorative material.<sup>1</sup> Using existing technologies such as CPP-ACP (Recaldent™) and fluorides, smooth surfaces of demineralized enamel can be remineralized, while glass ionomers can interact chemically with the *affected dentine* (the softened, non-infected demineralized layer) in the depth of the cavity and drive remineralization. Areas of unsupported enamel can be supported with adhesive restorative materials and margins do not have to be extended into theoretically “caries-free” areas. A remineralizing material such as glass ionomer cement can be laminated with another material such as composite resin, to better withstand masticatory stresses of the oral environment.<sup>2</sup> This has been termed the “Sandwich Restoration”.

Minimal clinical cavity access can be defined as the least amount of enamel removal required to enable adequate access for visualisation and removal of the *infected dentine*. This is best accomplished with the use of magnification as this greatly aids the preservation of tooth structure. Use of binocular loupes should almost be considered a prerequisite for carrying out sound minimally invasive dentistry.

### Micro-preparation techniques

Micro-preparation techniques can involve a number of cutting modalities:

- Micro-preparation and fissurotomy burs;
- Sonic tooth preparation;
- Air abrasion;
- Chemomechanical methods; and
- Lasers.



Figure 1. A KaVo air abrasion tip utilizing additional water spray for decreased patient sensitivity.

### Micro-preparation and fissurotomy burs

Many manufacturers are now producing smaller burs for cavity preparation using MI techniques. The burs are spherical, tapered or elliptical. Examples include fissurotomy burs (SS White, USA) and narrow diamond burs (Brassler, USA). Used with the aid of magnification, these allow very precise preparation of teeth. Micropreparation burs allow the dentist to conservatively explore and modify the fissures even when caries has spread laterally along the dentinoenamel junction.

### Sonic tooth preparation

This utilizes the vibrational energy of ultrasonically vibrated metal tips, rather than rotation. It allows precise minimal cutting preparation using diamond coated tips, such as those of the SonicSys system (KaVo, Biberach, Germany).

### Air abrasion

This utilizes a stream of small (27.5 micron diameter) aluminium oxide particles under air pressure to remove tooth substance by brittle fracture (Figure 1). It produces less

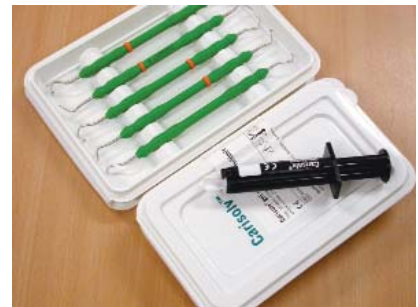

Figure 2. Use of mechanical hand instrumentation with Carisolv. Courtesy Mediteam Dental, Gothenburg, Sweden.

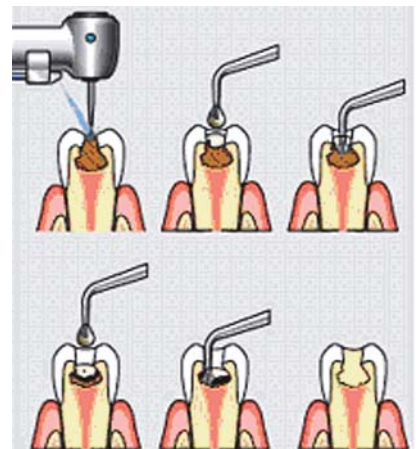


Figure 3. The Carisolv gel in a 2-component syringe, with specifically designed hand instruments.

heat, sound or vibration compared to high speed instrumentation and does not induce microfractures or microcrazing that follows high speed instrumentation.<sup>3</sup>

Air abrasion can be used for:

- Cutting small pit and fissure cavities;
- Removal of composite and porcelain;
- Clean and prepare tooth surfaces of debris, metal, porcelain and composite prior to adhesive restoration; and
- Minor class II, class III, class IV and class V cavity preparations.

Air abrasion preparation is very conservative and can produce a very fine cut, selectively removing softened carious enamel over dentinal caries to allow access to the infected dentine.<sup>4</sup> Air abrasion is well tolerated by patients, with the advantage that cavities 2.0-3.0 mm deep can be prepared without the use of local anaesthesia.

### Chemomechanical method

This involves the application of a chemical solution to the infected carious dentine, selectively softening the carious dentine by proteolysis, facilitating its removal with mechanical hand instruments, and without affecting sound non-carious dentine.<sup>5,6</sup> The most efficient system available is Carisolv™ (Mediteam Dental - Gothenburg, Sweden), (Figures 2 and 3). Carisolv can be used solely, or in combination with other methods that may be required to gain access to the lesion. This method is particularly suitable for root surface caries and large cavitated coronal cavities. It has the advantage of not usually requiring the use of local anaesthesia.

### Lasers

The process of effective cutting of tooth structure using an Erbium:YAG laser was first reported by Hibst at the University of Ulm in the mid 1980's.<sup>7</sup> A number of lasers have been investigated for their suitability in cavity preparation and the solid state systems based on erbium (Er:YAG and Er,Cr:YSGG) are the most effective (Figures 4 and 5).

The mechanism of hard tissue removal is basically an explosive subsurface expansion of the interstitially trapped water, with the rapid ejection of tooth particles in the opposite direction from the incoming laser beam. As carious tooth structure has a higher water content than sound tooth, it is rapidly and effectively removed by the laser energy.<sup>8</sup>

Lasers have the advantages of reduced need for anaesthesia (development of a laser analgesia effect), have a low annoyance factor (less noise and vibration than rotary instrumentation) and leave the cavity surface suitable for adhesive restorations. However the use of laser lacks tactile sense, and depending on the material and type of laser, the rate of cutting of tooth structure may be slightly slower than with a high speed rotary bur.

### The role of disinfection in arresting dental caries

Destroying the bacteria present within a carious lesion or changing the ecological niche to encourage remineralization, are current topics of research. These treatment

approaches are especially applicable to open lesions such as root caries which cannot be sealed and where the caries process will continue unchecked.

Methodologies that could be considered:

- Ozone (O<sub>3</sub>); and
- Photo-activated disinfection (PAD).

### Ozone

Ozone (O<sub>3</sub>) is a powerful oxidizing agent which neutralizes acids and its effects on cell structures, metabolism and microorganisms are well-documented in published papers in both dentistry and medicine.<sup>9-11</sup> Research has shown that ozone disrupts the cell walls of microorganisms (bacteria and viruses) within seconds, leading to immediate func-



Figure 4. Er:YAG dental laser (KEY 3, KaVo, Germany).

tional cessation. This rapid effect has clinical significance, as the potential for microbial resistance to this treatment modality is insignificant. In view of its powerful oxidizing properties, O<sub>3</sub> can also attack many biomolecules such as the cysteine, methionine and the histidine residues of proteins and change the surface ecology of the carious lesion. Remineralization from salivary ions occurs readily, due to the surface changes on the exposed dentinal tubules.

### Chemistry

Ozone (O<sub>3</sub>) is naturally produced by the photodissociation of molecular O<sub>2</sub> into activated oxygen atoms, which then react with further oxygen molecules. This transient radical anion rapidly becomes protonated, generating HO<sub>3</sub>, which, in turn, decomposes to an even more powerful oxidant, the hydroxyl radical (OH).

### Indications

Exposed root surfaces in aged individuals with gingival recession are more susceptible to caries.<sup>12-13</sup> The micro flora of primary root caries lesions has been shown to contain large numbers of acidogenic and aciduric microorganisms, which correlate with the severity of root caries.<sup>14-18</sup> Ozone can now be considered as a clinical alternative management strategy for root caries, and this statement is well supported in the increasing volume of published research on this topic. Reversal of primary root caries lesions is associated with remineralization and a corresponding reduction in acidogenic and aciduric micro-organisms.<sup>19,20</sup> This research has

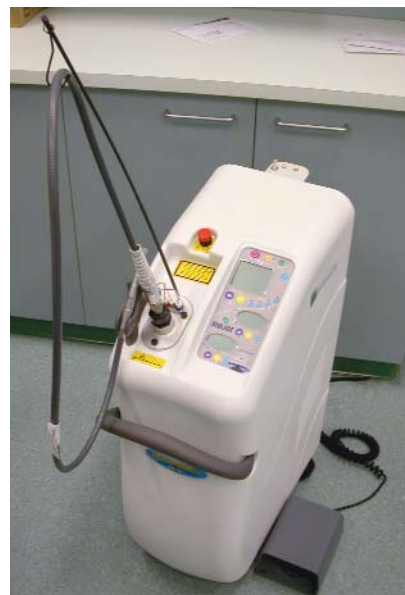

Figure 5. Er,Cr:YSGG dental laser (Waterlase, Biolase, USA).

shown that ozone also breaks up the acidic products of cariogenic bacteria, which may be important in the aetiology of the developing carious lesion. Research by Baysan,<sup>18</sup> reported that ozone application for either 10 or 20 seconds was effective in achieving a kill of 99% or more (99.9% after 20 seconds) of micro-organisms in primary root carious lesions *in vitro* and *in vivo* and an application for a period of 10 seconds was still capable of reducing the numbers of *streptococcus mutans* and *S. sobrinus in vitro*.

### Photo-Activated Disinfection

Photo-activated disinfection (PAD) is a method of disinfecting or sterilizing a site (tissues, wounds and lesions of the oral cavity) by topically applying a photosensitizing agent (a dye) and irradiating the site with laser light at a wavelength absorbed



by the photosensitizing agent. Destruction of the microbes occurs without damage to other tissues at the site.

### Mechanism of action

The low power laser energy in itself is not particularly lethal to bacteria, but is useful for photochemical activation of the dye. The photosensitive dyes release reactive oxygen species which cause membrane and DNA damage to the microorganisms. The oxygen free radicals from this process are broken down readily by catalase (present in all tissues and peripheral blood) and lactoperoxidase (in saliva). PAD does not give rise to deleterious thermal effects on teeth or soft tissues. PAD has been shown to be effective for killing bacteria in complex biofilms, which are typically resistant to the action of antimicrobial agents.<sup>21-23</sup> It can be used effectively in carious lesions, since visible red light transmits well across dentine.<sup>23</sup> Major clinical applications of PAD include disinfection of root canals, periodontal pockets, sites of peri-implantitis and deep carious lesions.<sup>24-25</sup>

An example of a PAD system is the Dentofex *Savedent* red diode laser with a wavelength of 635 nm that uses tolonium chloride as the photosensitizing dye to sterilize a carious cavity and the infected dentinal tubules. Such systems would have obvious clinical relevance in terms of managing deep dentinal carious lesions. With the ability to rapidly and effectively sterilize the floor of deep carious lesions (to 1.0 mm), more conservative approaches to the removal of demineralized and infected tooth structure could be used. Of note, PAD is still able to exert significant effects even when the cariogenic organisms are protected in a matrix of demineralized dentine.<sup>23,26</sup>

### Summary

General conservative dentistry is failing to address the causes of the frequent failure of our dental restorations. This 'Repeat - Restoration' cycle occurs, because general dentists are not trained to diagnose and treat dental caries as a disease, to the detriment of our patients' oral health. Modern dentistry needs to take a biological approach to the management of dental caries, where the emphasis must be on diagnosing the oral ecological balance and effecting biological change in the oral biofilm.

By altering dietary and lifestyle patterns and through the use of new diagnostic tests for plaque and saliva, we can monitor patient compliance and modify the disease risk.

New products such as CPP-ACP (Recaldent®) can provide biologically available calcium, phosphate and fluoride ions to enhance tooth remineralization and with the use of sodium bicarbonate rinses (pH elevation) and biocides, we can favorably alter the pathogenicity of the biofilm. New materials and techniques in prevention and repair of tooth damage involve the use of biomimetic restorative materials to heal dentine caries and through the use of new technologies such as ozone or photo-activated disinfection (PAD), we can disinfect carious cavities and encourage remineralization.

*Originally published in Shanghai Journal of Stomatology, 2006, 15(3):225-249. Reprinted with permission from Shanghai Journal of Stomatology, 2006, 15(3):225-249 © College of Stomatology, Shanghai Jiao Tong University.*

### CPD POINTS AVAILABLE

*Continuing Education credits are available on this article for subscribers by answering the questionnaire at [www.dentalpractice.com.au](http://www.dentalpractice.com.au)*

*Drs Andrew Brostek and Andrew Bochenek are in general dental practice Perth, in Western Australia. Both have been using the minimal invasive approach in their clinical practices for many years, and have been early technologies which support this approach to patient care, including air and ozone. They have taken a holistic and comprehensive approach to exemplify the approach described in this article.*

*Dr Laurence Walsh is head of school and Professor of Dental Science at the University of Queensland, Brisbane. He has worked clinically in the field of special needs and published extensively on preventive and minimal intervention. Through his research work, he has contributed to the development and assessment of a number of the technologies which underpin minimal intervention dentistry which are now in clinical use in Australia and elsewhere.*

### References

- Buonocore MG. A simple method of increasing the adhesion of acrylic filling materials to enamel surfaces. *J Dent Res*, 1955;34:849-53.
- Mount GJ. An atlas of Glass Ionomer Cements: A Clinician's Guide. London, Martin Dunitz, 1994.
- Stanley HR. Traumatic capacity of high-speed and ultrasonic dental instrumentation. *J Am Dent Assoc*. 1961 Dec (63);749-66.
- Rainey TJ. Air abrasion: An emerging standard of care in conservative operative dentistry. *Dent Clin Nth Am* 2002; 185-209.

- Morrow LA, Hassall DC, Watts DC, Wilson NHF. A chemomechanical method of caries removal. *Dental Update*. 2000;27:398-401.
- Ericson D, Zimmerman M, Raber H, Gotrick B, Bornstein R, Thorell J. Clinical evaluation of efficacy and safety of a new method for chemomechanical removal of caries; A multi-centre study. *Caries Res*. 1999;33(3):171-177.
- Hibst R, Keller U. Experimental studies of the application of the Er:YAG laser on dental hard substances: 1. Measurement of the ablation rate. *Lasers Surg Med* 1989;9:338-344.
- Belikov AV, Erofeev AV, Shumilin VV, Trachuk AM. Comparative study of 3 micron laser action on different hard tissue samples using free running pulsed Er-doped YAG, YSGG, YAP and YLF lasers. *SPIE*. 1993;2080:60-67.
- Bocci V. Biological and clinical effects of ozone. Has ozone therapy a future in medicine? *Br J Biomed Sc*. 1993;56:270-279.
- Bocci V. Ozone as a bioregulator. Pharmacology and toxicology of ozone therapy today. *J Biol Regul Homeost agents* 1996;10:31-53.
- Lynch E (ed). *Ozone: The Revolution in Dentistry*. Berlin: Quintessence Publishing Co. 2005.
- Hellyer PH, Beighton D, Heath MR. Root caries in older people attending a general dental practice in East Sussex. *Br Dent J* 1990;169:201-206.
- Galan D, Lynch E. Epidemiology of root caries. *Gerodontology* 1993; 10:59-71.
- Lynch E, Beighton D. Relationships between mutans streptococci and perceived treatment need of primary root caries lesions. *Gerodontology* 1993;10:98-104.
- Lynch E, Beighton D. A comparison of primary root caries lesions classified according to colour. *Caries Res*. 1994;28:233-239.
- Schuppach P, Osterwalder V, Gunnenheim B. Human root caries: Microbiota in plaque covering sound, carious and arrested carious root surfaces. *Caries Res* 1995;29:382-395.
- Brailsford SR, Lynch E, Beighton D. The isolation of *Actinomyces naeslundii* from sound root surfaces and root caries lesions. *Caries Res*. 1998;32:100-106.
- Baysan A. Management of primary root caries using ozone therapies. PhD thesis, University of London, 2002.
- Beighton D, Lynch E, Heath MR. A microbiological study of primary root caries lesions with different treatment needs. *J Dent Res* 1993;73:623-629.
- Lynch E. The diagnosis and management of primary root caries. PhD thesis. London: University of London, 1994.
- Dobson J, Wilson M. Sensitization of oral bacteria in biofilms to killing by light from a low power laser. *Arch Oral Biol*. 1992;37:883-887.
- Sarker S, Wilson M. Lethal photosensitization of bacteria in subgingival plaque from patients with chronic periodontitis. *J Perio Res*. 1993;28:204-210.
- Wilson M. Bacterial effect of laser light and its potential use in the treatment of plaque related diseases. *Int Dent J*. 1994;44:181-189.
- Walsh LJ. The current status of low level laser therapy in dentistry, Part 2. Hard tissue applications. *Aust Dent J*. 1997;42:302-306.
- Dortbudak O, Haas R, Bernhart T, Mailath-Pokorny G. Lethal photosensitization for decontamination of implant surfaces in the treatment of peri-implantitis. *Clin Oral Impl Res*. 2001;12:104-108.
- Stringer GJ, et al. Lethal laser photosensitisation of *Streptococcus mutans* with a visible red diode laser. *Aust Dent J*. 2000;45(suppl):S22.